

Research article

The liver is a common non-exocrine target in primary Sjögren's syndrome: A retrospective review

Mariana J Kaplan* and Robert W Ike

Address: Department of Internal Medicine, Division of Rheumatology, University of Michigan Health System, Ann Arbor, Michigan, USA

E-mail: Mariana J Kaplan* - makaplan@umich.edu; Robert W Ike - rike@umich.edu

*Corresponding author

Published: 13 September 2002

Received: 16 April 2002

BMC Gastroenterology 2002, 2:21

Accepted: 13 September 2002

This article is available from: <http://www.biomedcentral.com/1471-230X/2/21>

© 2002 Kaplan and Ike; licensee BioMed Central Ltd. This article is published in Open Access: verbatim copying and redistribution of this article are permitted in all media for any non-commercial purpose, provided this notice is preserved along with the article's original URL.

Abstract

Background: The autoimmune destruction of exocrine glands that defines primary Sjögren's syndrome (1°SS) often extends to non-exocrine organs including the liver. We aimed to determine the prevalence of liver disease in patients with 1°SS and to evaluate the association of this complication with other non-exocrine features and serologic markers of autoimmunity and systemic inflammation.

Methods: We reviewed 115 charts of patients with 1°SS and further analyzed the 73 cases that fulfilled the European Epidemiology Center Criteria, seeking evidence for clinical and subclinical liver disease.

Results: Liver function tests had been determined in 59 of the 73 patients. Of those, 29 patients (49.1%) had abnormal liver function tests including 20.3% with clinically overt hepatic disease. Liver disease was the most common non-exocrine feature in this cohort. Risk factors for abnormal liver function tests were distributed similarly between the patients with and without liver disease. In 60% of patients with abnormal liver function tests no explanation for this complication was found except for 1°SS. Liver involvement was significantly more common in 1°SS patients who also had evidence of lung, kidney and hematological abnormalities. Patients with abnormal liver function tests were also more likely to have an elevated sedimentation rate and a positive anti-ENA during the course of their disease.

Conclusion: Liver involvement is a common complication in 1°SS. Its presence correlates with systemic disease. We consider that this complication should be routinely sought in patients with 1°SS, especially when a positive anti-ENA or evidence of systemic inflammation is found.

Background

Primary Sjögren's syndrome (1°SS) is a systemic autoimmune disorder characterized by dry eyes (keratoconjunctivitis sicca), dry mouth (xerostomia) as well as involvement of other exocrine glands. While 1°SS is typically considered an autoimmune exocrinopathy, the immune destruction can often extend to affect non-exocrine

organs. Around 25 % of patients with 1°SS can present with involvement of other organs such as the thyroid, central nervous system, lungs, kidney and liver. The association of liver disease and 1°SS was suggested more than 40 years ago [1]. While liver involvement in 1°SS has been considered "rare" [2] only a few clinical studies specifically address this complication and evaluate the association

of liver function tests abnormalities with the severity of 1°SS [3–6].

Liver diseases associated with 1°SS include primary biliary cirrhosis (PBC)-autoimmune cholangitis [8–10], autoimmune hepatitis [5,6], viral hepatitis (B and C) [11–21], sclerosing cholangitis [22], and nodular regenerative hyperplasia [23]. In addition, chronic lymphocytic sialadenitis has been found in patients with different types of liver cirrhosis [16–24].

We report the results of a review of cases undertaken to determine the prevalence of abnormal liver function tests (LFTs) and liver disease in patients with 1°SS referred to a tertiary care center and the association of abnormal LFTs with other systemic features and autoimmunity markers of 1°SS.

Methods

A total of 115 charts of patients seen at the University of Michigan Medical Center between 1968 and 1996 were reviewed and those that had been coded as Sjögren's syndrome were considered for analysis. Patients were captured from the Rheumatology outpatient clinic, the Rheumatology consults records, different in-patient services and also, through the review of the salivary gland biopsies performed at this institution during those years.

Of these 115 patients, we included only those patients who fulfilled the European Epidemiology Center Criteria (EECC) for 1°SS [26,27]. We also excluded patients with evidence of other connective tissue diseases, since this would make them be considered secondary SS. Of the 115 charts reviewed, 73 cases (55 women and 18 men, median age 53) fulfilled EECC for 1°SS and were initially included for analysis. We reviewed each chart for any record of non-exocrine manifestations of the disease (Table 1), clinical

and laboratory evidence of liver disease. We considered patients to have clinically significant liver disease when the following symptoms and signs were present in association with abnormal liver function tests: jaundice, ascites, spider angiomas, liver palms, palmar erythema, gynecomastia, loss of hair, reduction in testicular size, evidence of collateral circulation, asterixis, pruritus secondary to cholestasis, light-colored stools, dark urine, abdominal pain, hepatomegaly, other signs of portal hypertension including esophageal varices and splenomegaly.

Laboratory studies reviewed included: a) liver function tests (aspartate amino-transferase (AST), alanine-amino transferase (ALT), alkaline phosphatase (AP), gamma-glutamyl transpeptidase (GGT), bilirubins, albumin, prothrombin time); b) serological markers of autoimmunity (antinuclear antibodies (ANA), antibodies to extractable nuclear antigens (ENA), rheumatoid factor (RF), anti-dsDNA (anti-double stranded DNA), cryoglobulins, anticardiolipin antibodies (ACL), anti-neutrophil cytoplasmic antibodies (ANCA); c) specific markers of autoimmune liver disease (antimitochondrial (AMA), anti-smooth muscle (ASM) and liver-kidney microsomal antibodies); d) viral hepatitis markers (A, B, C); e) liver imaging studies (abdominal ultrasound, abdominal CT, nuclear medicine studies) ; f) when available, results of liver biopsies.

Subclinical liver disease was considered present when abnormal LFTs (aminotransferases, alkaline phosphatase, GGT or bilirubin) were detected but no clinical signs, symptoms or other laboratory findings of liver dysfunction were found. In addition, we searched for any mention of drug use (immunosuppressive, NSAIDs or others), transfusions, tobacco use and abuse of alcohol or drugs, as well as their association with the onset of abnormal liver function tests.

Table 1: Non-exocrine clinical features considered part of 1°SS for this study (excluding liver)

1	Lung	Lymphocytic interstitial pneumonia, fibrosing alveolitis, pseudolymphoma, lymphoma, pulmonary amyloidosis
2	Renal	Renal tubular acidosis type I, nephrogenic diabetes insipidus, chronic interstitial nephritis, immune-mediated glomerulonephritis
3	Cardiovascular	Myocarditis, pericarditis, pericardial effusion, Raynaud's
4	Gastrointestinal	Atrophic gastritis, pancreatitis
5	Vasculitis	Mononeuritis multiplex, axonal neuropathy, purpura
6	Hematologic	Coombs positive hemolytic anemia, leukopenia, lymphopenia, thrombocytopenia, hypoplastic bone marrow
7	Peripheral nervous system	Axonal neuropathy, mononeuritis multiplex
8	Central nervous system	Aseptic meningitis, cerebral vasculitis, CVA, TIAs, multiple sclerosis "like" changes
9	Endocrine	Autoimmune thyroid disease
10	Musculoskeletal	Arthritis, arthralgias, myositis

CVA: central vascular accident TIA: transient ischemic attack

Table 2: Clinical characteristics of the patients studied

ORGAN	(# of patients) n = 59	FREQUENCY N (%)
Exocrine features	(59)	59(100)
* Xerostomia or xerophthalmia		
Liver		
* Abnormal liver function tests	(29)	29 (49.1)
* Physical findings of liver disease	(12)	
Lung		
* LIP	(6)	16 (27.1)
* Amyloid	(1)	
* Other ILD	(9)	
Heart		
* Pericarditis	(2)	4 (6.7)
* Myocarditis	(2)	
CNS		
* CNS vasculitis	(4)	22 (37.2)
* Aseptic meningitis	(4)	
* MS "like " disease	(3)	
* Transverse myelitis	(2)	
* CVAs, TIAs	(9)	
PNS		
* Peripheral neuropathy	(16)	25 (42.3)
* Mononeuritis multiplex	(8)	
* Myopathy	(1)	
Kidney		
* Tubular disorders	(12)	21 (35.5)
* Glomerulonephritis	(4)	
* Others	(5)	
Skin		23 (38.9)
Raynaud's		15 (25.4)
Vasculitis		18 (30.5)
Blood		
* BM hypoplasia	(2)	22 (37.2)
* Hemolytic anemia	(3)	
* Autoimmune thrombocytopenia	(4)	
* Leukopenia	(4)	
* Prothrombotic states	(3)	
* Lymphadenopathy	(6)	
Arthritis and arthralgias	(20)	20 (33.8)

LIP: lymphocytic interstitial pneumonia ILD: interstitial lung disease MS: multiple sclerosis CNS: central nervous system

Statistical analysis

The statistical analysis included descriptive measures (means, standard deviations and ranges). Comparison of results of patients with and without liver disease was done using t-tests of continuous variables and Fisher's exact test or χ^2 for categoric measures.

Results

Of the 115 charts reviewed, 73 cases (55 women and 18 men, median age 53) fulfilled EECC for 1°SS and were initially included for analysis. Of the 73 patients, a 54% of them (40 patients) have had a salivary gland biopsy performed. In all these patients, the biopsy confirmed the diagnosis of Sjögren's syndrome. All patients studied had

objective evidence of 1°SS, including keratoconjunctivitis sicca, positive labial salivary gland biopsy, autoantibodies and/or salivary gland hypofunction. We excluded those patients without these objective criteria of 1°SS and also those who did not fulfill EECC criteria.

The mean age at time of onset of disease was 45 ± 20.5 years old and disease duration was $4.9 \text{ years} \pm 4.5 \text{ years}$ (mean \pm range). Liver function tests had been determined in 59 patients (80.8 %) and abnormal liver function tests were found in 29 of the 59 patients (49.1 %). Further analysis was then undertaken in those patients in whom LFTs had been measured. The clinical and laboratory characteristics of these patients are shown in Tables 2 and 3.

Table 3: Autoimmunity markers of the patients studied

MARKER	FREQUENCY n (%) Total = 59	Mean ± SEM
↑ WESR	27 (45.7)	45 ± 10 mm/hr
↑ CRP	13 (22)	1.5 ± 0.6 mg/dl
+ANA	43 (72.8)	
+RF	27 (45.7)	65 ± 10 IU/ml
+ANCA	7 (11.9)	
+ENA	27 (45.7)	
+ANTI-DSDNA	9 (15.2)	12 ± 5 IU/ml
+CRYOGLOBULINS	2 (3.3)	
+ACL	7 (11.8)	25 ± 3 GPL

WESR: Westegren erythrocyte sedimentation rate CRP: C-reactive protein ANA: antinuclear antibodies RF: Rheumatoid factor ANCA: anti-neutrophil cytoplasmic antibody ENA: extracted nuclear antigens Anti-dsDNA: anti-double stranded DNA (by Farr assay) ACL: anticardiolipin antibody

Table 4: Risk factors

RISK FACTOR	W/LIVER DISEASE	W/O LIVER DISEASE	P
AGE	55 ± 10 years	53 ± 15 years	0.7
MALE SEX	7/29	8/30	1
FEMALE SEX	22/29	22/30	1
ALCOHOL ABUSE	2/29	3/30	1
VIRUS	5/20	0/11	0.13
<u>DRUGS</u>			
* STEROIDS	15/29	13/30	0.606
* CYCLOPHOSPHAMIDE	3/29	5/30	0.706
* AZATHIOPRINE	4/29	3/30	0.706
* HYDROXYCHLOROQUINE	9/29	4/30	0.125
* NSAIDS	15/29	14/30	0.705

For these SS patients studied, abnormal LFTs were more common than any other potential non-exocrine features of SS. Clinical evidence of liver disease, defined in methods section, was found in 12 patients (20.3%), all of whom had abnormal liver function tests. Two deaths occurred in the population studied, both attributed to liver failure. An additional patient required a liver transplant. In all cases, the diagnosis of 1°SS antedated the onset of liver disease or its diagnosis. Markers of viral hepatitis, sought in 39 patients, were found only in 4. Two patients carried the surface antigen of hepatitis B virus and one had antibodies to hepatitis C virus. In a liver biopsy of a patient who lacked serological markers for hepatitis viruses, hepatitis B virus was detected by *in situ* hybridization.

Risk factors for liver disease were identified in 40% of the patients with abnormal liver function tests and are described in Table 4. No association with tobacco use was found. Only 5 patients had documented evidence of to-

bacco consumption. We found no significant differences in risk factors for abnormal liver function tests among patients with or without hepatic involvement. Therefore, in 60% of the patients with sub clinical or clinical evidence of liver disease, no clear explanation for the abnormal LFTs was found, except for the association with 1°SS.

The pattern of biochemical liver abnormalities was mainly hepatocellular (defined as predominant increase of AST and/or ALT in comparison with AP and/or bilirubins) in 11 cases; cholestatic (defined as predominant increase in AP and/or bilirubins compared with AST and/or ALT) in 3 and mixed (evidence of both cholestatic and hepatocellular damage) in 8 cases. Abnormalities were persistent (present on every occasion when measured more than once) in 19 patients (65.5% of those with abnormal LFTs), intermittent (presence of LFT abnormalities was not found in all determinations) in 9 (31%) and in one case (3.5%) there was only one determination of liver

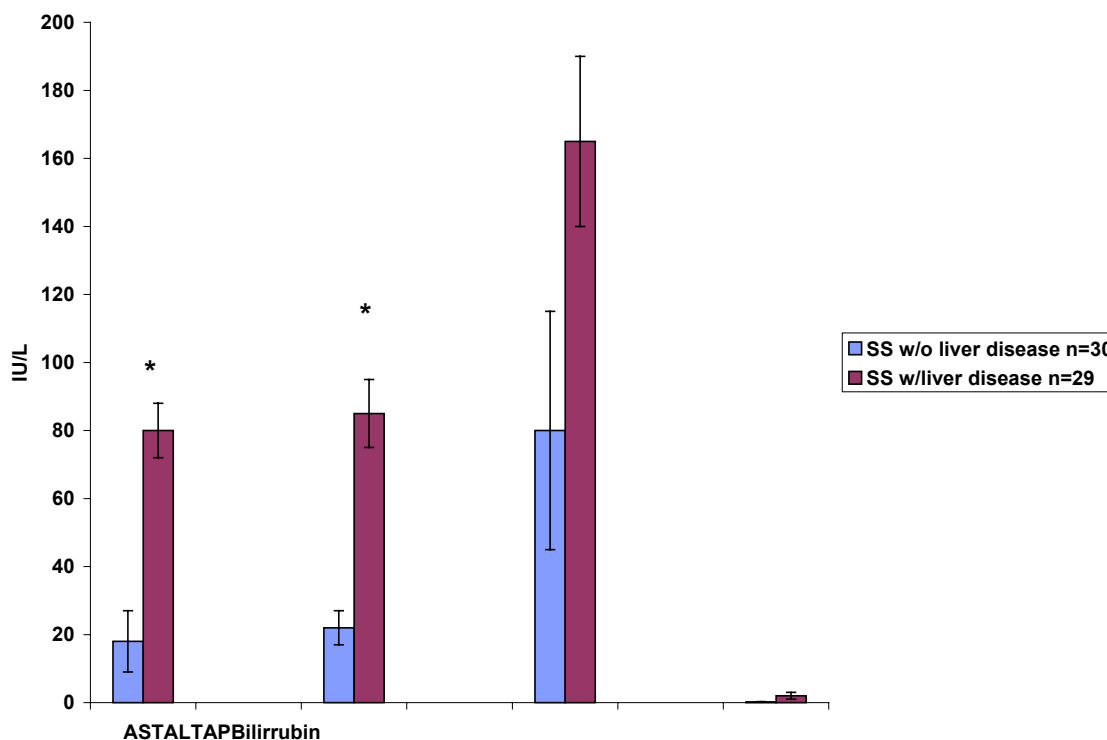


Figure 1
Liver function test values in Sjögren's patients with and without liver involvement. AP = alkaline phosphatase, AST = aspartate amino transferase, ALT = alanine amino transferase. Results represent mean ± range, * p < 0.05, n = 59 patients, with liver dysfunction n = 29; without liver dysfunction n = 30

function tests. The pattern of liver enzyme abnormalities is shown in Figure 1. None of the patients with abnormal liver function tests had clinical evidence of muscle involvement that could explain the high levels of aminotransferases. Activity of CPK or aldolase was not elevated when measured in 15 of the 29 patients with abnormal liver function tests. Anti-mitochondrial antibodies (AMA) and anti-smooth muscle antibodies (ASMA) were sought in 5 patients, with positive ASMA in 2.

The association of abnormal liver function tests with other non-exocrine features of 1°SS is shown in Figure 2. Patients with abnormal liver function tests were more likely to have lung, kidney or hematological manifestations, when compared to Sjögren's patients without liver dis-

ease. Presence of other non-exocrine features of 1°SS was not influenced by prevalence of liver diseases.

Regarding laboratory test results, patients with liver disease were more likely to have an elevated sedimentation rate at some point during the course of their disease. A positive anti-ENA (anti-Ro, anti-Ro/La, and/or anti-RNP) was also associated with an increased prevalence of abnormal liver function tests (Figure 3). The sample was too small to determine whether a specific ENA was associated with liver disease. Other markers of systemic inflammation or autoimmunity did not correlate with the presence or absence of LFT abnormalities.

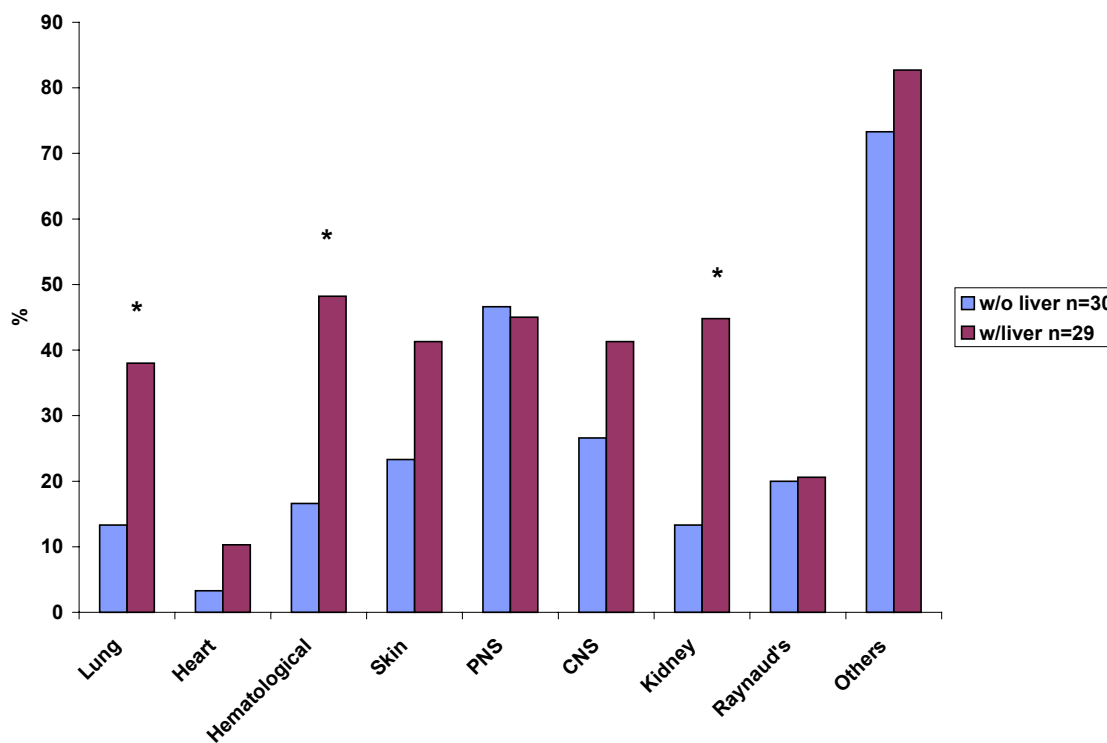


Figure 2
Association of liver disease with other extraglandular manifestations in patients with Sjögren's syndrome. Figure represents percentage of patients with and without liver disease who presented with other non-exocrine features of 1°SS. Patients with liver disease = 29; patients without liver disease = 30, * p < 0.05.

Liver biopsies, done in 8 patients, disclosed post-viral chronic active hepatitis (3), cryptogenic cirrhosis (2), and one case each of post-viral cirrhosis, alcoholic hepatitis, and autoimmune hepatitis.

Discussion

In this group of Sjögren's patients seen at a tertiary care center, abnormal liver function tests were found to be a common non-exocrine feature of 1°SS. The prevalence of this association was found to be higher in our study than in other previous series [2-7]. The true prevalence could be even higher since liver enzyme profiles were not done in all patients. The prevalence suggested in previous reports ranges from 6 to 58 %, but the definition of hepatic disease varies from the unspecific (e.g. hepatomegaly) to

well proven cases of liver disease [1-7,28]. Denko in 1960 reported that 12% of patients with SS had hepatosplenomegaly [29]. Other studies done in the 1960's also confirmed hepatomegaly in 18-20% of patients with SS [30,31]. In 1970, Whaley reported liver disease in 6% of patients with SS and mentioned an association with anti-mitochondrial antibodies [2]. In 1986, Tsianos and co-workers described 22 SS patients with gastrointestinal complications, called from a large cohort; only two patients had liver disease, each with chronic active hepatitis [4]. Other studies have reported variable prevalence [3,28] and different histopathological findings in liver biopsies ranging from cholestatic liver damage (stage I primary biliary cirrhosis) to chronic active hepatitis due to hepatitis C virus.

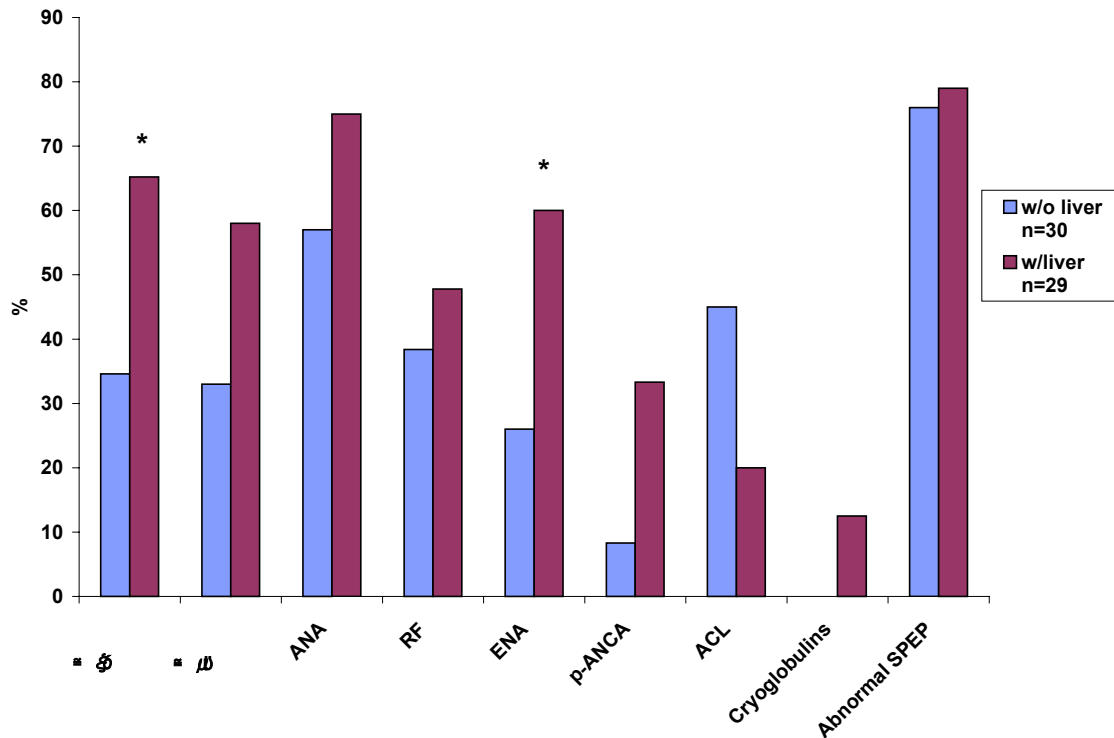


Figure 3
Association of liver disease with laboratory abnormalities in patients with Sjögren's syndrome. Figure represents percentage of patients with and without liver disease who presented with serological evidence of autoimmunity or inflammation. Patients with liver disease = 29; patients without liver disease = 30, * $p < 0.05$.

In our study, liver disease was associated with other non-exocrine manifestations of 1°SS, specifically those affecting lung, kidney and blood cells. Those patients with serological evidence of systemic inflammation, as shown by an elevated sedimentation rate, were more likely to have liver test abnormalities. Also, the presence of a positive anti-ENA correlated positively with hepatic disease. An association of ENA response with liver disease has been described in children with autoimmune hepatitis, where anti-ENA-positive patients demonstrated more severe liver test abnormalities than those who were anti-ENA-negative [32]. In another study, a 15% of patients with various chronic liver diseases were found to be anti-RNP positive [33].

With etiopathogenesis of 1°SS still an open question [34], a possible role of hepatitis C virus (HCV) has drawn attention. Recent studies have mentioned HCV incidence in patients with 1SS ranging from 14–19% [11,12,16,18,21]. Phenotypic characterization of the minor salivary glands with immunohistochemistry in patients with hepatitis C virus infection and/or 1°SS has given conflicting results [14,15]. Some reports mention that the salivary gland findings are strikingly similar in patients with liver disease associated with HCV infection than in those with 1°SS [12], while others mention distinctive differences between both groups regarding focus score, expression of surface markers in lymphocytes infiltrating the salivary glands and in epithelial cells, as well as differences in the degree of inflammation [14,15]. Transgenic mice models that

carry the HCV envelope genes develop an exocrinopathy affecting salivary and lachrymal glands [19]. Expression of autoimmunity markers also tends to differ between HCV-infection and 1°SS. Positive ENAs are rarely seen in HCV-patients. Also, in most cases sicca symptoms are not present in individuals with HCV as compared with the 1°SS population. Although the prevalence of viral hepatitis markers in our group of patients with liver disease was very low and did not account for most of the cases with abnormal liver function tests, these markers were not sought in a small percentage of these patients. It is important to note that HCV appears to account for a subgroup of patients with exocrine complaints in which half the cases might meet the definition for SS according to European and Manthorpe criteria. However, this subgroup is characterized by the absence of clinical manifestations observed in 1°SS, and the absence of anti-Ro and anti-La [35].

An aberrant interaction between lymphocytes and different epithelial tissues has been proposed as a mechanism for the damage seen in different organs in 1°SS [36]. Since it has been suggested that the target tissue involved in the autoimmune histopathologic lesions of 1°SS might be the epithelium [37], it is interesting that the findings in our study point to the association of liver disease with pulmonary and renal abnormalities, all which are characterized by epithelial damage [38,39]. Epithelial cells have been proposed to be active participants rather than passive targets in the chronic immune response in 1°SS but further studies are needed to establish the role of liver epithelial cells in the pathogenesis of hepatic damage in this disease, including the analysis of HLA expression and cytokine secretion pattern in these cells.

The co-existence of liver disease and the presence of circulating AMAs in Sjögren's patients sera has been pointed as an indicator that liver pathology might be autoimmune and similar to that of primary biliary cirrhosis [4,7,8,10]. In previous studies, a pericholangial lymphocytic infiltration similar to that found in stage I of primary biliary cirrhosis, has been reported in 1°SS with abnormal liver function tests or positivity for AMA [4,7]. In our review of cases, we found predominance in hepatocellular liver damage rather than cholestatic disease, which would argue against a PBC-type of liver damage. Other authors had proposed that SS associated with PBC should be considered a form of secondary SS that resembles more the "sicca complex" with exocrine features seen in patients with rheumatoid arthritis [40,41].

Limitations of the study come primarily from being a retrospective analysis. Since the patients were studied in a tertiary care referral center, the severity of the disease and the prevalence of the manifestations might be different from the general 1°SS population. Furthermore, in many

cases, Sjögren's syndrome diagnosis had been sought because of otherwise unexplained non-exocrine features. While we could not find an association between use of NSAIDs or other medications and prevalence of liver function tests abnormalities, the study design did not allow us to exclude the possibility of over-the-counter (OTC) medication use that could have affected LFT's measurement. Drug toxicity is certainly an important factor to be considered. However, given that most patients had persistent rather than intermittent abnormalities of LFTs and that the use of hepatotoxic drugs was not elicited in the majority of patients with liver abnormalities, a toxic effect of medications could not be established.

Conclusions

Based on the results of this study, we consider that an evaluation for clinical and serological evidence of liver disease should be done in every patient with 1°SS, particularly if there is evidence of other non-exocrine complications or serological evidence of systemic inflammation. Although no other diagnosis explaining liver disease may be found, the disorders for which treatment might be beneficial (e.g. immunosuppressants for autoimmune hepatitis, interferon-alpha for viral hepatitis, ursodeoxycolic acid for primary biliary cirrhosis) warrant a diligent search in all cases of 1°SS with abnormal liver function.

Competing interests

None.

Authors' contributions

Both authors contributed equally to the paper.

Acknowledgements

We thank Mr. Steven Knowlton for his expert secretarial assistance.

References

- Christianson J: **Corneal changes in a case of hepatitis.** *Acta Ophthalmol* 1954, **32**:161-164
- Whaley K, Goudie RB, Williamson J, Nuki G, Dick WC, Buchanan WW: **Liver disease in Sjögren's syndrome and rheumatoid arthritis.** *Lancet* 1970, **1**:861-863
- Skopuli FN, Barbatis C, Moutsopoulos HM: **Liver involvement in primary Sjogren's syndrome.** *Br J Rheumatol* 1994, **33**:745-748
- Tsianos EB, Vasakos S, Drosos AA, Malamou-Mitsi VD, Moutsopoulos HM: **The gastrointestinal involvement in primary Sjögren's syndrome.** *Scand J Rheumatol* 1986, **61**:151-155
- Lindgren S, Manthorpe R, Eriksson S: **Autoimmune liver disease in patients with primary Sjögren's syndrome.** *J Hepatol* 1994, **20**:354-358
- Masaki N, Hayashi S: **Autoimmune liver disease complicating Sjogrens syndrome.** *Nippon Rinsho* 1995, **53**:2530-2535
- Webb J, Whaley K, MacSween RN, Nuki G, Dick WC, Buchanan WW: **Liver disease in rheumatoid arthritis and Sjögren's syndrome. Prospective study using biochemical and serological markers of hepatic dysfunction.** *Ann Rheum Dis* 1975, **34**:70-81
- Hansen BU, Lindgren S, Eriksson S, Henricsson V, Larsson A, Manthorpe R, Warfulunge G: **Clinical and immunological features of Sjögren's syndrome in patients with primary biliary cirrhosis with emphasis on focal sialadenitis.** *Acta Med Scand* 1988, **224**:611-619
- Archimandritis A, Tjivras M, Tsiirantonaki M, Hatzis G, Delladetsima I: **Sjogren's syndrome with antimitochondrial antibody-nega-**

- tive primary biliary cirrhosis: a case of autoimmune cholangitis.** *J Clin Gastroenterol* 1995, **20**:268-278
10. Alarcon-Segovia D, Diaz-Jouanen E, Fishbein E: **Features of Sjogren's syndrome in primary biliary cirrhosis.** *Ann Intern Med* 1973, **79**:31-38
 11. Gumber SC, Chopra S: **Hepatitis C: a multifaceted disease. Review of extrahepatic manifestations.** *Ann Intern Med* 1995, **123**:515-520
 12. Haddad J, Deny P, Munz-Gotheil C, Ambrosini JC, Trinchet JC, Pateron D, Mal F, Callard P, Beaugrand M: **Lymphocytic sialadenitis of Sjogren's syndrome associated with chronic hepatitis C virus liver disease.** *Lancet* 1992, **339**:321-323
 13. Pirisi M, Scott C, Fabris C, Ferraccioli G, Soardo G, Ricci R, Toniutto P, Avellini C, Vitulli D, Miotti AM: **Mild sialoadenitis: a common finding in patients with hepatitis C virus infection.** *Scand J Gastroenterol* 1994, **29**:940-942
 14. Scott CA, Avellini C, Desinan L, Pirisi M, Ferraccioli G, Bardus P, Fabris C, Casatta L, Bartoli E, Beltrami CA: **Chronic lymphocytic sialoadenitis in HCV-related chronic liver disease: comparison of Sjogren's syndrome.** *Histopathology* 1997, **30**:41-48
 15. Coll J, Gambus G, Corominas J, Tomas S, Esteban JI, Guardia J: **Immunohistochemistry of minor salivary gland biopsy specimens from patients with Sjogren's syndrome with and without hepatitis C virus infection.** *Ann Rheum Dis* 1997, **56**:390-392
 16. Jorgensen C, Legouffe MC, Perney P: **Sicca syndrome associated with hepatitis C virus infection.** *Arthritis Rheum* 1996, **39**:1166-1171
 17. Pawlotsky JM, Ben Yahia M, Andre C, Voisin MC, Intrator L, Roudot-Thoraval F, Deforges L, Duvoux C, Zafrani ES, Duval J: **Immunological disorders in C virus chronic active hepatitis: a prospective case-control study.** *Hepatology* 1994, **19**:841-848
 18. Wattiaux MJ: **Syndrom de Gougerot Sjogren et virus de l'hépatite C: quels liens?** *Presse Medicale* 1997, **26**:652-657
 19. Koike K, Moriya K, Ishibashi K, Yotsuyagani H, Shintani Y, Fujie H, Kurokawa K, Matura Y, Miyamura T: **Sialadenitis histologically resembling Sjogren syndrome in mice transgenic for hepatitis C virus envelope genes.** *Proc Natl Acad Sci USA* 1997, **94**:233-236
 20. Aprosina ZG, Serov VV, Lopatkina TN: **The hepatitis B virus as a probable etiological factor in Sjogren's disease.** *Ter Arkh* 1993, **65**:73-78
 21. Garcia Carrasco M, Ramos M, Cervera R, Font J, Vidal J, Munoz FJ, Miret C, Espinosa G, Ingelmo M: **Hepatitis C virus infection in primary Sjogren's syndrome: prevalence and clinical significance in a series of 90 patients.** *Ann Rheum Dis* 1997, **56**:173-175
 22. Montefusco PP, Geiss AC, Bronzo RL, Randall S, Kahn E, McKinley MJ: **Sclerosing cholangitis, chronic pancreatitis and Sjogren's syndrome: a syndrome complex.** *Am J Surg* 1984, **147**:822-826
 23. Gonzalez-Alvaro I, Carmona-Ortell L, Amigo-Etxenagusia A, Castaneda Sanz S: **Nodular regenerative hyperplasia of the liver and primary Sjogren's syndrome.** *J Rheumatol* 1994, **21**:168-169
 24. Oscott CA, Avellini C, Desinan L, Pirisi M, Ferraccioli GF, Bardus P, Fabris C, Casatta L, Bartoli E, Beltrami CA: **Chronic lymphocytic sialoadenitis in HCV-related chronic liver disease: comparison of Sjogren's disease.** *Histopathology* 1987, **30**:41-48
 25. Czaja AJ: **The variant forms of autoimmune hepatitis.** *Ann Intern Med* 1996, **125**:588-598
 26. Vitali C, Bombardieri S, Moutsopoulos HM, Balestrieri G, Bencivelli W, Bernstein RM, Bjerrum KB, Braga S, Coll I, De Vita S: **Preliminary criteria for the classification of Sjogren's syndrome.** *Arthr Rheum* 1993, **36**:340-347
 27. Vitali C, Bombardieri S: **The diagnosis of Sjogren's syndrome: definition and validation of classification criteria for this disorder.** *Ann Med Interne (Paris)* 1998, **149**:12-16
 28. Vogel C, Wittenborg A, Reichart P: **The involvement of liver in Sjogren's syndrome.** *J Oral Surg* 1980, **50**:26-31
 29. Denko CW, Bergstral PM: **The sicca syndrome (Sjogren's syndrome):** *Arch Intern Med* 1960, **105**:849-853
 30. Vanselow NA, Dodson VN, Angell DE: **A clinical study of Sjogren's syndrome.** *Ann Intern Med* 1963, **58**:124-129
 31. Bloch KJ, Buchanan WW, Wohl MJ: **Sjogren's syndrome. A clinical pathological and serological study of sixty-nine cases.** *Medicine (Baltimore)* 1965, **44**:187-192
 32. Gregorio GV, Davies ET, Mieli-Vergani G, Vergani D: **Significance of extractable nuclear antigens in childhood autoimmune liver disease.** *Clin Exp Immunol* 1995, **102**:308-313
 33. Konikoff F, Shoenfeld Y, Isenberg DA, Barrison I, Sobe T, Theodor E, Slor H: **Anti-RNP antibodies in chronic liver disease.** *Clin Exp Rheumatol* 1987, **5**:359-361
 34. Moutsopoulos HM: **Immunopathology of Sjogren's syndrome. More questions than answers.** *Lupus* 1993, **2**:209-211
 35. Loustaud-Ratti V, Riche A, Liozon E, Labrousse F, Soria P, Rogez S, Babany G, Delaire L, Denis F, Vidal E: **Prevalence and characteristics of Sjogren's syndrome or sicca syndrome in chronic hepatitis C virus infection: a prospective study.** *J Rheumatol* 2001, **28**:2245-2251
 36. Fox RI, Kang HI: **Pathogenesis of Sjogren's syndrome.** *Rheum Dis Clin North Am* 1992, **18**:517-538
 37. Moutsopoulos HM, Kordossis T: **Sjogren's syndrome revisited. Autoimmune epithelitis.** *Br J Rheumatol* 1995, **3**:204-206
 38. Siamopoulos KC, Mavridis AK, Elisaf M, Drosos AA, Moutsopoulos HM: **Kidney involvement in primary Sjogren's syndrome.** *Scand J Rheumatol* 1986, **61**:156-160
 39. Constantopoulos SH, Papadimitriou CS, Moutsopoulos HM: **Respiratory manifestations in primary Sjogren's syndrome: A clinical, functional and histologic study.** *Chest* 1985, **88**:226-229
 40. St Clair EW, Angellilo JC, Singer KH: **Expression of cell adhesion molecules in the salivary gland microenvironment of Sjogren's syndrome.** *Arthr Rheum* 1992, **35**:62-66
 41. Moutsopoulos HM, Chised TM, Mann DL, Klippel JH, Fauci AS, Frank MM, Lawley TJ, Hamburger MJ: **Sjogren's syndrome (sicca syndrome).** *Current Issues. Ann Intern Med* 1980, **92**:212-220

Pre-publication history

The pre-publication history for this paper can be accessed here:

<http://www.biomedcentral.com/1471-230X/2/21/pre-pub>

Publish with **BioMed Central** and every scientist can read your work free of charge

"BioMedCentral will be the most significant development for disseminating the results of biomedical research in our lifetime."

Paul Nurse, Director-General, Imperial Cancer Research Fund

Publish with **BMC** and your research papers will be:

- available free of charge to the entire biomedical community
- peer reviewed and published immediately upon acceptance
- cited in PubMed and archived on PubMed Central
- yours - you keep the copyright

Submit your manuscript here:

<http://www.biomedcentral.com/manuscript/>



BioMedCentral.com

editorial@biomedcentral.com