

Research article

Open Access

## Influence of rectal prolapse on the asymmetry of the anal sphincter in patients with anal incontinence

Henri Damon<sup>1</sup>, Luc Henry<sup>1</sup>, Sabine Roman<sup>1</sup>, Xavier Barth<sup>2</sup> and François Mion\*<sup>1</sup>

Address: <sup>1</sup>Fédération des Spécialités Digestives, Hôpital E. Herriot, 69437 Lyon cedex 03, France and <sup>2</sup>Urgences Viscérales, Hôpital E. Herriot, 69437 Lyon cedex 03, France

Email: Henri Damon - henri.damon@wanadoo.fr; Luc Henry - luc.henry@chu-lyon.fr; Sabine Roman - sroman@ifrance.com; Xavier Barth - xavier.barth@chu-lyon.fr; François Mion\* - francois.mion@chu-lyon.fr

\* Corresponding author

Published: 19 August 2003

Received: 07 April 2003

*BMC Gastroenterology* 2003, **3**:23

Accepted: 19 August 2003

This article is available from: <http://www.biomedcentral.com/1471-230X/3/23>

© 2003 Damon et al; licensee BioMed Central Ltd. This is an Open Access article: verbatim copying and redistribution of this article are permitted in all media for any purpose, provided this notice is preserved along with the article's original URL.

### Abstract

**Background:** Anal sphincter defects have been shown to increase pressure asymmetry within the anal canal in patients with fecal incontinence. However, this correlation is far from perfect, and other factors may play a role. The goal of this study was to assess the impact of rectal prolapse on anal pressure asymmetry in patients with anal incontinence.

**Methods:** 44 patients, (42 women, mean age: 64 (11) years), complaining of anal incontinence, underwent anal vector manometry, endo-anal ultrasonography (to assess sphincter defects) and pelvic viscerogram (for the diagnosis of rectal prolapse). Resting and squeeze anal pressures, and anal asymmetry index at rest and during voluntary squeeze were determined by vector manometry.

**Results:** Ultrasonography identified 19 anal sphincter defects; there were 9 cases of overt rectal prolapse, and 14 other cases revealed by pelvic viscerogram (recto-anal intussusception). Patients with rectal prolapse had a significantly higher anal sphincter asymmetry index at rest, whether patients with anal sphincter defects were included in the analysis or not (30 (3) % versus 20 (2) %,  $p < 0.005$ ). Among patients without rectal prolapse, a higher anal sphincter asymmetry index during squeezing was found in patients with anal sphincter defects (27 (2) % versus 19 (2) %,  $p < 0.03$ ).

**Conclusions:** In anal incontinent patients, anal asymmetry index may be increased in case of anal sphincter defect and/or rectal prolapse. In the absence of anal sphincter defect at ultrasonography, an increased anal asymmetry index at rest may point to the presence of a rectal prolapse.

### Background

Anal incontinence is a multi-factorial disease, associating various causes such as anal sphincter defects, pelvic nerve lesions and anatomical pelvic floor disorders. Endo-anal ultrasonography allows the identification of anal sphincter defects [1,2]; we have also observed that patients with rectal prolapse occasionally revealed an asymmetrical aspect of the sphincter.

Anal vector manometry has been claimed to allow for the identification of sphincter defects through increased anal pressure asymmetry index. Indeed, we and others [3,4] have shown that some correlation exists between the radial size of external anal sphincter defects and increased anal asymmetry index. However, this correlation is far from perfect and other factors such as rectal prolapse may be at bay to increase anal pressure asymmetry.

The goal of this study was to assess the impact of both anal sphincter defects and rectal prolapse on the anal asymmetry index as determined by anal vector manometry.

## Methods

We thus studied the results of anal vector manometry performed in 44 patients (42 women and 2 men, mean age: 64 years-old, range: 23 to 79) complaining of anal incontinence, in whom the diagnostic work-up included an anal ultrasonography (EAU) (performed through the endo-anal and endo-vaginal route) and a dynamic pelvic viscerogram (PV) (barium opacification of pelvic organs), allowing the identification of patients with anal sphincter defects and / or rectal prolapse. Indeed, both situations may be missed despite a thorough clinical investigation: anal sphincter defects disclosed only by EAU are a frequent occurrence, and intra-anal rectal prolapse (or recto-anal intussusception) may be under-diagnosed by clinical examination only.

Anal incontinence was considered when patients experienced significant accidental bowel leakages of liquid or solid stools, recurrent episodes of anal soiling, or urgent stools with a retention time of less than fifteen minutes. The severity of anal incontinence symptoms was assessed using the clinical score proposed by Jorge et al [5]. Associated symptoms such as stress urinary incontinence and severe dyschesia (defined as the need of digital anal manoeuvres to obtain defecation) were also inquired after. Past surgical and obstetrical histories were obtained in all patients.

EAU was performed using a rigid 360° rotating probe with a transducer frequency of 7 or 10 MHz (Brüel & Kjaer, Naerum, Denmark): internal and external anal sphincter defects were identified as previously described [6,7], and the radial size of the defects measured.

Anal vector manometry was performed using a radial 8-lumen perfused catheter (Zynectics Medical, Inc, Salt Lake City, UT), an automated catheter-puller at 10 mm/s (Uro Synectics, Medtronic, Rueil-Malmaison, France): three pull-outs were performed through the anal canal at rest and during voluntary squeeze. The mean values for anal pressures and the anal asymmetry indexes, at rest and during voluntary squeeze, were calculated using a commercially available software (Polygram 98, Medtronic, Rueil-Malmaison, France). The anal asymmetry index is calculated by adding the 8 pressures obtained at the high pressure zone (defined as the anal region with mean pressures above 80% of the maximal mean pressure), dividing this by the maximum pressure multiplied by the number of channels and subtracting this value from 1. Values are reported as percentage values, with a perfect symmetry having a value of zero.

Pelvic viscerogram allowed for the identification of intra-anal or the confirmation of exteriorised rectal prolapse. PV consists of a dynamic X-Ray examination of the position and movements of pelvic organs at rest, during straining and squeezing with patients sitting on a chair. Filling of the rectum is obtained with a home-made barium paste (barium sulfate cooked with corn starch and water; vaginal marking is done by injection of a 20 ml syringe containing 10 ml of liquid barium sulfate (to mark the vaginal walls) and 10 ml of the barium paste to mould the vaginal cavity. Finally, the bladder is filled with 200 ml of water-soluble contrast medium (Telebrix) through a small catheter left in place during the examination. Intra-anal rectal prolapse was defined as the invagination of part of the rectal mucosa within the anal canal. A rectal invagination above the upper limit of the anal canal was not considered for the diagnosis of rectal prolapse.

Statistical analyses between groups were performed by one-way ANOVA or Chi<sup>2</sup>-test as appropriate. Results are expressed as mean (SEM), unless otherwise indicated. Statistical significance was set to be 0.05.

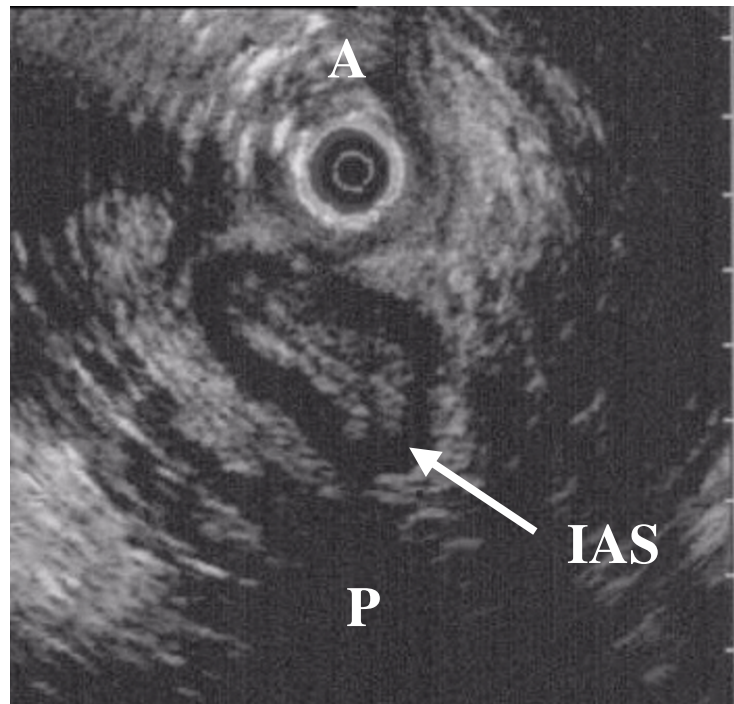
## Results

The relevant demographic and clinical data of the 44 patients are summarized in table 1.

**Table 1: Demographic and clinical characteristics of the study population (44 patients with anal incontinence)**

Sex (Women/Men)	42/2
Mean Age (Range)	64 (23–79)
past history of perineal surgery (%)	31 (73.8 %)
past hysterectomy (%)	22 (52.4 %)
parous women (%)	35 (83.3 %)
number of vaginal deliveries (range)	3.2 (1–11)
Forceps use in parous women (%)	11 (31.4 %)
Mean clinical score of anal incontinence (range)	13 (6–19)
Mean duration of symptoms in months (range)	52 (3–480)
Associated symptoms of dyschesia (%)	9 (20.5 %)
Associated symptoms of stress urinary incontinence (%)	19 (43.2 %)

Among the 44 patients, EAU identified 19 patients with an anal sphincter defect (43.2%): 8 isolated defects of the external sphincter, 3 isolated defects of the internal sphincter and 8 combined defects of both sphincters. Full-thickness rectal prolapse was clinically evident in 9 patients, and PV showed 14 cases of recto-anal intussusception. Although these two entities may not necessarily represent two stages of the same disease, they both impose a stress on the anal canal muscles, and are pooled as rectal



### Figure 1

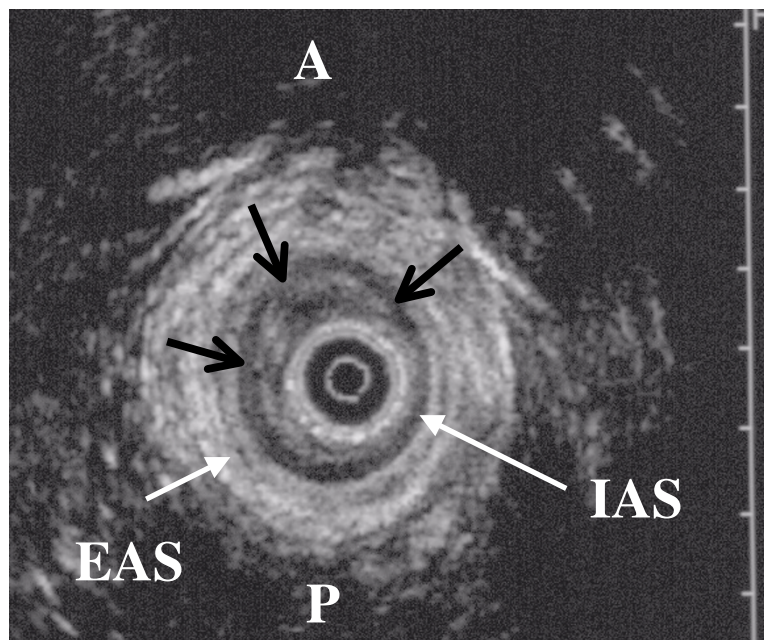
Endo-vaginal ultrasonography of anal sphincter in a patient with rectal prolapse: irregular and asymmetrical appearance of the internal anal sphincter (IAS arrow), without defect (A: anterior, and P: posterior).

prolapse cases (23 of 44 patients, 52.3%). The coexistence of both abnormalities (anal sphincter defect and rectal prolapse) was found in ten patients (22.7%).

In some patients, anal ultrasonography showed an asymmetrical aspect of the anal sphincter when a rectal prolapse was present (figure 1), or a heterogeneous thickening of the internal hyperechoic layer corresponding to the anal sub-mucosa (figure 2), while these aspects were never seen in the absence of a rectal prolapse (figure 3).

The 2 groups of patients with and without rectal prolapse did not differ in terms of age, past histories of vaginal deliveries, perineal or gynaecological surgery, score of anal incontinence, associated urinary symptoms. Severe dyschesia was observed more frequently in the rectal pro-

lapse group (8 of 23 patients (34.8 %), versus 1 of 21 patients (4.7 %) without rectal prolapse,  $p < 0.04$ ). The results of anal vector manometry are summarized in tables 2 and 3. Patients with rectal prolapse had an anal sphincter asymmetry index at rest significantly increased, while the differences were not statistically significant for the other manometric variables (table 2). With regard to the presence or absence of anal sphincter defects, the results of vector manometry were different only for the anal sphincter asymmetry index during squeezing (table 3). When taking into account only the patients without anal sphincter defects (25 patients, of whom 13 had a rectal prolapse), the anal asymmetry index at rest was still the only manometric variable significantly increased when a rectal prolapse was present (30(3)% vs 16(2) %,  $p < 0.03$ ) (figure 4).



**Figure 2**

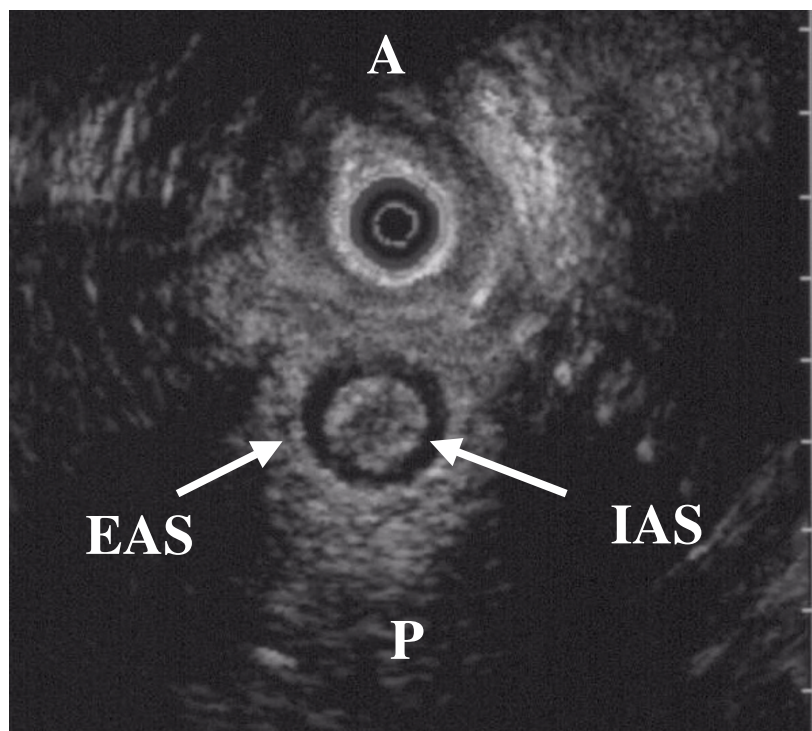
Endo-anal ultrasonographic view of the anal sphincter in a patient with rectal prolapse: black arrows indicate a submucosal thickening in the anterior right and left quadrants of the internal anal sphincter (IAS: internal anal sphincter; EAS: external anal sphincter; A: anterior; P: posterior).

The other parameters of vector manometry were not different (data not shown). Finally, the results of vector manometry were similar in patients with full thickness rectal prolapse or recto-anal intussusception, whether patients with anal sphincter defects were included or not (data not shown).

### Discussion

To our knowledge, the results of this study identify for the first time the role of rectal prolapse in the determination of anal sphincter pressure asymmetry. In patients with anal incontinence, anal vector manometry has been used mainly to evaluate the existence of anal sphincter defects. Although it can not precisely locate the defect [8], in comparison with anal ultrasonography, recent studies have shown that an increased anal asymmetry index was well

correlated to the presence of a large anal sphincter defect on ultrasonography [3,4]. However, an increased anal asymmetry index without anal sphincter defect is not a rare occurrence in our experience. Our results clearly demonstrate that rectal prolapse or recto-anal intussusception may also increase anal asymmetry index, in the same proportions as anal sphincter defects. This is of importance because rectal prolapse is a well known cause of anal incontinence, because the clinical diagnosis of this condition may be sometimes difficult and because a specific treatment of the prolapse may improve the symptoms of anal incontinence [9–11]. On the other hand, recto-anal intussusception may cause significant symptoms of obstructive defecation (dyschesia), which may in the long term leads to anal incontinence [12]. On a functional point of view, rectal prolapse has been shown to be asso-



**Figure 3**  
 For comparison, an endo-vaginal ultrasonographic view of a normal anal sphincter of a patient without rectal prolapse. (IAS: internal anal sphincter; EAS: external anal sphincter; A: anterior; P: posterior).

**Table 2: Results of anal vector manometry in patients with or without rectal prolapse (patients with anal sphincter defects included).**

	Rectal prolapse	No rectal prolapse	p
number of patients	23	21	
Mean (SEM) anal resting pressure (cm H <sub>2</sub> O)	45 (7)	67 (11)	0.08
Mean (SEM) anal squeeze pressure (cm H <sub>2</sub> O)	88 (13)	114 (16)	0.2
Mean (SEM) ASAI at rest (%)	30 (3)	20 (2)	0.0046
Mean (SEM) ASAI during squeezing (%)	25 (2)	20 (2)	0.19

(ASAI: anal sphincter asymmetry index)

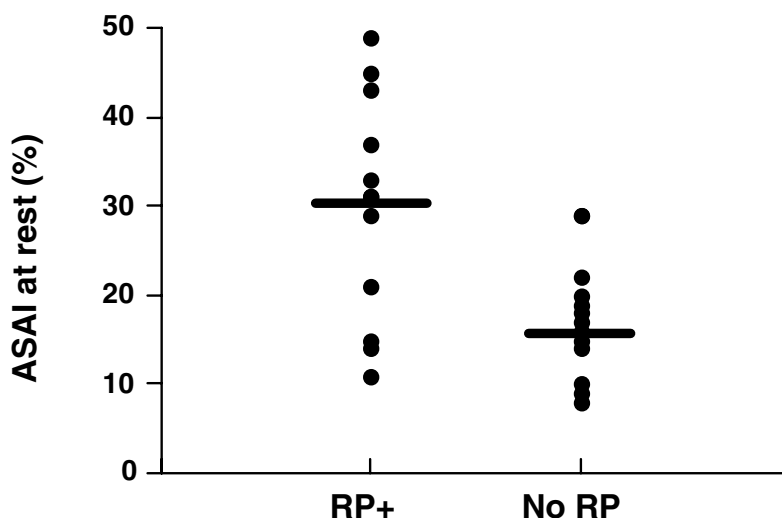
ciated with a decreased resting anal pressure [13–15]. Several hypotheses have been suggested to explain this manometric finding: associated pudendal neuropathy [16], functional inhibition of the mechanical activity of the anal internal sphincter [13], or associated defects of the anal sphincter [17]. From our results, we believe that the distortion of the anal sphincter induced by the rectal

prolapse, as identified by anal vector manometry, may be responsible for a decreased contractile activity (functional inhibition). Interestingly, in the group of patients without anal sphincter defect, only the anal sphincter asymmetry index at rest was significantly increased when a rectal prolapse was present, while in the group of patients without rectal prolapse, only the anal sphincter asymmetry during

**Table 3: Results of anal vector manometry in patients with or without anal sphincter defect (patients with rectal prolapse included).**

	Anal sphincter defect	Normal sphincter	p
number of patients	19	25	
Mean (SEM) anal resting pressure (cm H <sub>2</sub> O)	54 (10)	56 (9)	0.8
Mean (SEM) anal squeeze pressure (cm H <sub>2</sub> O)	93 (16)	107 (13)	0.5
Mean (SEM) ASAI at rest (%)	28 (3)	23 (2)	0.2
Mean (SEM) ASAI during squeezing (%)	27 (2)	19 (2)	0.024

(ASAI: anal sphincter asymmetry index)



**Figure 4**

Individual results of anal sphincter asymmetry index at rest (ASAIr) in patients without anal sphincter defect, depending on the presence (13 patients) or the absence (12 patients) of rectal prolapse. The black bars represent the mean value in each group ( $p < 0.03$ ).

squeezing was significantly increased when an anal sphincter defect was present (with a majority of external sphincter defects). These 2 observations indicate that rectal prolapse alters mainly the internal anal sphincter functions, while the consequences of external anal sphincter defects are as expected modifying anal voluntary squeeze.

**Conclusions**

Our results demonstrate that in patients with anal incontinence, an increased anal asymmetry index as determined by vector manometry may not be related to anal sphincter

defects only. Rectal prolapse and recto-anal intussusception may indeed increase anal asymmetry index, especially at rest. This functional asymmetry is often seen on EAU as a heterogenous thickening of the internal sphincter muscular layer. This typical aspect should thus be looked for during EAU evaluation of anal incontinent patients, in addition to the search for anal sphincter defects. In difficult cases, defecography or pelvic viscerogram should be performed to distinguish between full thickness rectal prolapse and recto-anal intussusception.

## Competing interests

None declared.

## Authors' contributions

HD carried out the echographic and manometric studies, and conceived of the study. LH carried out the pelvic viscerograms. SR participated in the design of the study. XB participated in the patients' enrolment and in the design of the study. FM participated in the design of the study and drafted the manuscript. All authors read and approved the final manuscript.

## References

1. Sultan AH, Kamm MA, Talbot IC, Nicholls RJ and Bartram CI: **Anal endosonography for identifying external sphincter defects confirmed histologically.** *Br J Surg* 1994, **81**:463-5.
2. Sultan A, Nicholls R and Kamm M: **Anal endosonography and correlation with in vitro and in vivo anatomy.** *Br J Surg* 1992, **80**:808-811.
3. Fynes MM, Behan M, O'Herlihy C and O'Connell PR: **Anal vector volume analysis complements endoanal ultrasonographic assessment of postpartum anal sphincter injury.** *Br J Surg* 2000, **87**:1209-14.
4. Damon H, Henry L, Barth X and Mion F: **Fecal incontinence in women with a past history of vaginal delivery: significance of anal sphincter defects detected by ultrasound.** *Dis Colon Rectum* 2002, **45**:1445-51.
5. Jorge JM and Wexner SD: **Etiology and management of fecal incontinence.** *Dis Colon Rectum* 1993, **36**:77-97.
6. Law PJ, Kamm MA and Bartram CI: **Anal endosonography in the investigation of faecal incontinence.** *Br J Surg* 1991, **78**:312-4.
7. Damon H, Henry L, Valette P and Mion F: **Endosonography in benign anorectal disease.** *Gastroenterol Clin Biol* 2001, **25**:35-44.
8. Yang YK and Wexner SD: **Anal pressure vectography is of no apparent benefit for sphincter evaluation.** *Int J Colorectal Dis* 1994, **9**:92-5.
9. Senapati A, Nicholls RJ, Thomson JP and Phillips RK: **Results of Delorme's procedure for rectal prolapse.** *Dis Colon Rectum* 1994, **37**:456-60.
10. Cirocco WC and Brown AC: **Anterior resection for the treatment of rectal prolapse: a 20-year experience.** *Am Surg* 1993, **59**:265-9.
11. Duthie GS and Bartolo DC: **Abdominal rectopexy for rectal prolapse: a comparison of techniques.** *Br J Surg* 1992, **79**:107-13.
12. Neill ME, Parks AG and Swash M: **Physiological studies of the pelvic floor in idiopathic faecal incontinence and rectal prolapse.** *Br J Surg* 1981, **68**:531-6.
13. Farouk R, Duthie GS, MacGregor AB and Bartolo DC: **Rectoanal inhibition and incontinence in patients with rectal prolapse.** *Br J Surg* 1994, **81**:743-6.
14. Felt-Bersma RJ, Janssen JJ, Klinkenberg-Knol EC, Hoitsma HF and Meuwissen SG: **Soiling: anorectal function and results of treatment.** *Int J Colorectal Dis* 1989, **4**:37-40.
15. Gammarota FV, Farouk R, Duthie GS and Bartolo DC: **The functional recovery of the internal anal sphincter and the restoration of continence after rectopexy for rectal prolapse.** *G Chir* 1992, **13**:527-31.
16. Birnbaum EH, Stamm L, Rafferty JF, Fry RD, Kodner IJ and Fleshman JW: **Pudendal nerve terminal motor latency influences surgical outcome in treatment of rectal prolapse.** *Dis Colon Rectum* 1996, **39**:1215-21.
17. Halligan S, Sultan A, Rottenberg G and Bartram CI: **Endosonography of the anal sphincters in solitary rectal ulcer syndrome.** *Int J Colorectal Dis* 1995, **10**:79-82.

## Pre-publication history

The pre-publication history for this paper can be accessed here:

<http://www.biomedcentral.com/1471-230X/3/23/prepub>

Publish with **BioMed Central** and every scientist can read your work free of charge

"BioMed Central will be the most significant development for disseminating the results of biomedical research in our lifetime."

Sir Paul Nurse, Cancer Research UK

Your research papers will be:

- available free of charge to the entire biomedical community
- peer reviewed and published immediately upon acceptance
- cited in PubMed and archived on PubMed Central
- yours — you keep the copyright

Submit your manuscript here:  
[http://www.biomedcentral.com/info/publishing\\_adv.asp](http://www.biomedcentral.com/info/publishing_adv.asp)

